



Case Report

Ovarian Remnant Syndrome: A Case Report

Leila Cristina Soares^{1*}, Ricardo José de Souza¹ and Jorge Luiz Alves Brollo²

¹Department of Gynecology, Rio de Janeiro State University, Rio de Janeiro, Brazil

²Department of Gynecology, Grande Rio University, Rio de Janeiro, Brazil

Abstract

Ovarian Remnant Syndrome (ORS) results from the presence of residual ovarian tissue after oophorectomy. The gold standard treatment for ORS is surgery. We report the case of a 44-year-old woman who presented with pelvic pain and was diagnosed as having ORS. She obtained relief after treatment with a gonadotropin-releasing hormone agonist and gabapentin. Avoiding surgery with its greater risks is desirable in ORS; however, more studies should be performed to assess the long-term effects of gabapentin.

Keywords: Gabapentin; GnRH agonist; Pelvic pain; Remnant ovarian syndrome

Introduction

Ovarian Remnant Syndrome (ORS) is a rare complication that arises as a consequence of residual ovarian tissue after an oophorectomy. It is characterized by pelvic pain, which can be chronic or cyclic. Surgery is considered the primary treatment but can present with certain difficulties [1].

We report an unusual case of ORS successfully treated with Gonadotropin-releasing Hormone agonist (GnRHa) in association with gabapentin.

Case Report

A 44-year-old Caucasian woman who underwent hysterectomy and bilateral adnexectomy 3 years earlier presented with pelvic pain. Clinical examination revealed no particular signs. A Follicle-stimulating Hormone (FSH) blood level of 11 IU/dL and transvaginal ultrasound revealed a left lateral mass of 46 × 38 mm. ORS was suspected and MRI confirmed a left cystic mass. Continuous oral contraceptives were prescribed, with no pain relief. She was then prescribed 10.8 mg goserelin acetate, a Gonadotropin-releasing

Hormone agonist (GnRHa). Because the treatment was multidisciplinary, she started taking gabapentin when she was already using a GnRHa. One month later, she reported clinical improvement. She stopped taking the GnRHa after 6 months and underwent magnetic resonance imaging that showed a suspected adnexal malignancy. She underwent laparotomy, and the remnant ovary was removed (Figure 1). Histopathological analysis revealed corpus albicans.

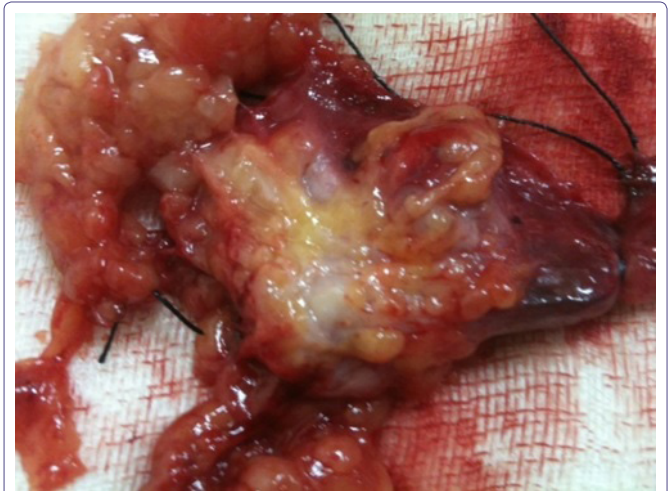


Figure 1: Remnant ovarian tissue removed by laparotomy.

Discussion

Ovarian remnant syndrome results from an unintentionally incomplete oophorectomy. In most patients, it seems that ORS results from an incidental implantation of ovarian tissue rather than an incomplete excision of a lesion [2].

Symptoms most often occur within the first 5 years of a previous surgery, although reports have shown patients whose initial surgeries were more than 20 years ago [1].

Dense periovarian adhesions and ovarian enlargement can make the identification of ovarian tissue difficult, and they are considered the predisposing factors of this disease. Both of those factors are present in severe endometriosis, the most typical preexisting disease [1]. The risk factors include pelvic inflammatory disease and adhesion [2].

The recurrence of pelvic symptoms is associated with the development of a hormonally functional follicular or corpus luteum cyst within the ovarian fragment, or with reactivation of endometriosis [3].

When the remaining ovary continues to produce sex steroids, the FSH levels remain low. Although the absence of this finding does not rule out the diagnosis, FSH levels <40 IU/dL indicate the presence of an ovarian remnant. A definitive diagnosis involves histologic confirmation of ovarian tissue obtained from the subsequent surgery [1].

The main treatment is surgery. Moreover, excision of remnant tissue requires retroperitoneal dissection [1]. Ovarian fragments may be difficult to localize, and reappearance of new fragments is

*Corresponding author: Leila Cristina Soares, Department of Gynecology, Rio de Janeiro State University, Pedro Ernesto University Hospital, Rio de Janeiro, Brazil, Tel: +55 88564796; E-mail: lcs1507@yahoo.com.br

Citation: Soares LC, de Souza RJ, Brollo JLA (2016) Ovarian Remnant Syndrome: A Case Report. J Reprod Med Gynecol Obstet 1: 002.

Received: November 22, 2015; Accepted: January 22, 2016; Published: February 08, 2016

possible. Ovulation-inducing drugs administered before surgery have been successful in stimulating the enlargement of such fragments, facilitating their location and removal [3].

Most clinical treatments do not seem to relieve symptoms and are often directed toward ovarian suppression. These include oral contraceptives such as danazol, GnRHa, and progestins [1].

Clinical treatments may increase the risk of ovarian cancer. There are controversies about the value of prophylactic oophorectomy in women with no increased risk for ovarian cancer. Epidemiological evidence suggest that annually about 1,000 cases of ovarian cancer are prevented for every 300,000 oophorectomies performed at the time of an elective hysterectomy in women over 40 years [4]. However, the risk of a woman with BRCA-1/BRCA-2 mutations developing ovarian cancer over a lifetime ranges from 16% to 54% [5]. If some ovary tissue is left in this population, there is a significant risk of ovarian cancer and clinical treatment is not indicated.

Gabapentin, a synthesized form of gamma-aminobutyric acid, an inhibitory neurotransmitter, is being increasingly prescribed for chronic pelvic pain and requires titration to achieve an efficacious dose [6]. Chronic gabapentin exposure reduces calcium currents because it binds to the $\alpha 2\delta$ -1 subunit of calcium channels. As voltage-gated calcium channels regulate various actions in the body, subtypes modulating pain are reduced [7]. In this case, it was used in association with a GnRHa with appreciable pain relief.

A medline search with the terms “remnant ovarian syndrome and gabapentin” revealed no previous reports about the use of gabapentin for ovarian remnant syndrome.

Conclusion

Although the literature reports failure in the clinical treatment of ORS, pain relief was obtained in this case by administering a GnRHa

in association with gabapentin. Avoiding surgery with its greater risks is desirable in ORS. However, the question remains whether ORS can be treated without surgery. We do not know if the pain improvement in this case was due to the association between GnRHa and gabapentin, or gabapentin alone. More studies should be performed to assess the long-term effects of gabapentin.

References

1. Kho RM, Abrao MS (2012) Ovarian remnant syndrome: etiology, diagnosis, treatment and impact of endometriosis. *Curr Opin Obstet Gynecol* 24: 210-214.
2. Chao HA (2008) Ovarian remnant syndrome at the port site. *J Minim Invasive Gynecol* 15: 505-507.
3. Rana N, Rotman C, Hasson HM, Redwine DB, Dmowski WP (1996) Ovarian remnant syndrome after laparoscopic hysterectomy and bilateral salpingo-oophorectomy for severe pelvic endometriosis. *J Am Assoc Gynecol Laparosc* 3: 423-426.
4. Shoupe D, Parker WH, Broder MS, Liu Z, Farquhar C, et al. (2007) Elective oophorectomy for benign gynecological disorders. *Menopause* 14: 580-585.
5. Finch A, Beiner M, Lubinski J, Lynch HT, Moller P, et al. (2006) Salpingo-oophorectomy and the risk of ovarian, fallopian tube, and peritoneal cancers in women with a BRCA1 or BRCA2 Mutation. *JAMA* 296: 185-192.
6. Horne AW, Critchley HO, Doust A, Fehr D, Wilson J, et al. (2012) GaPP: a pilot randomised controlled trial of the efficacy of action of gabapentin for the management of chronic pelvic pain in women: study protocol. *BMJ Open* 2.
7. Yan PZ, Butler PM, Kurowski D, Perloff MD (2014) Beyond neuropathic pain: gabapentin use in cancer pain and perioperative pain. *Clin J Pain* 30: 613-629.